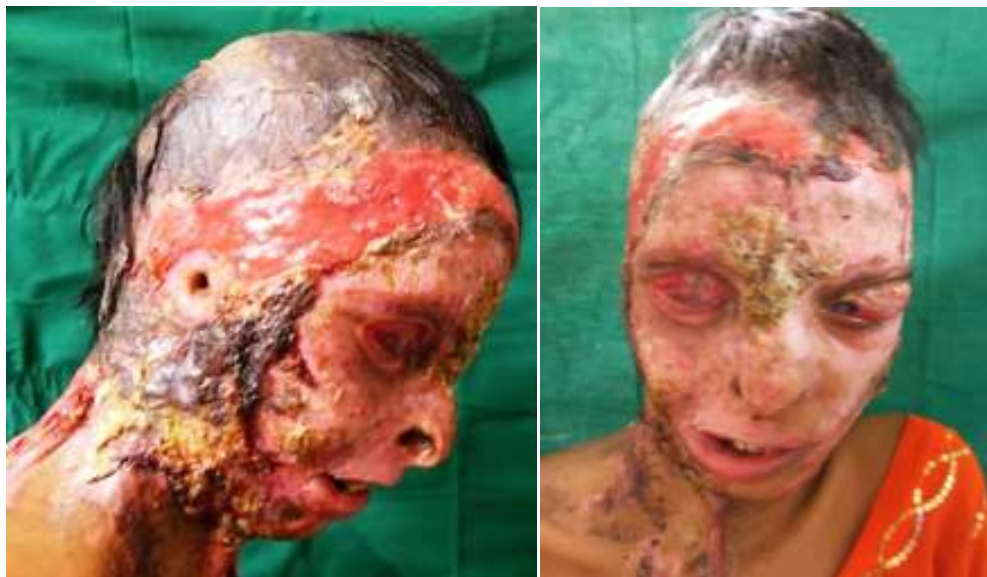

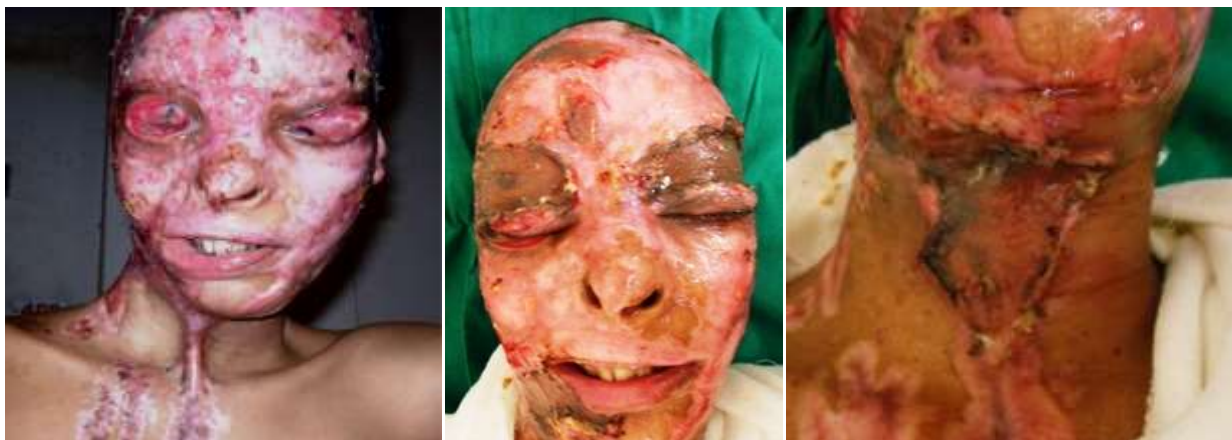STORYLINE OF VICTIMS OF ACID ATTACK

1. Ms. L B B

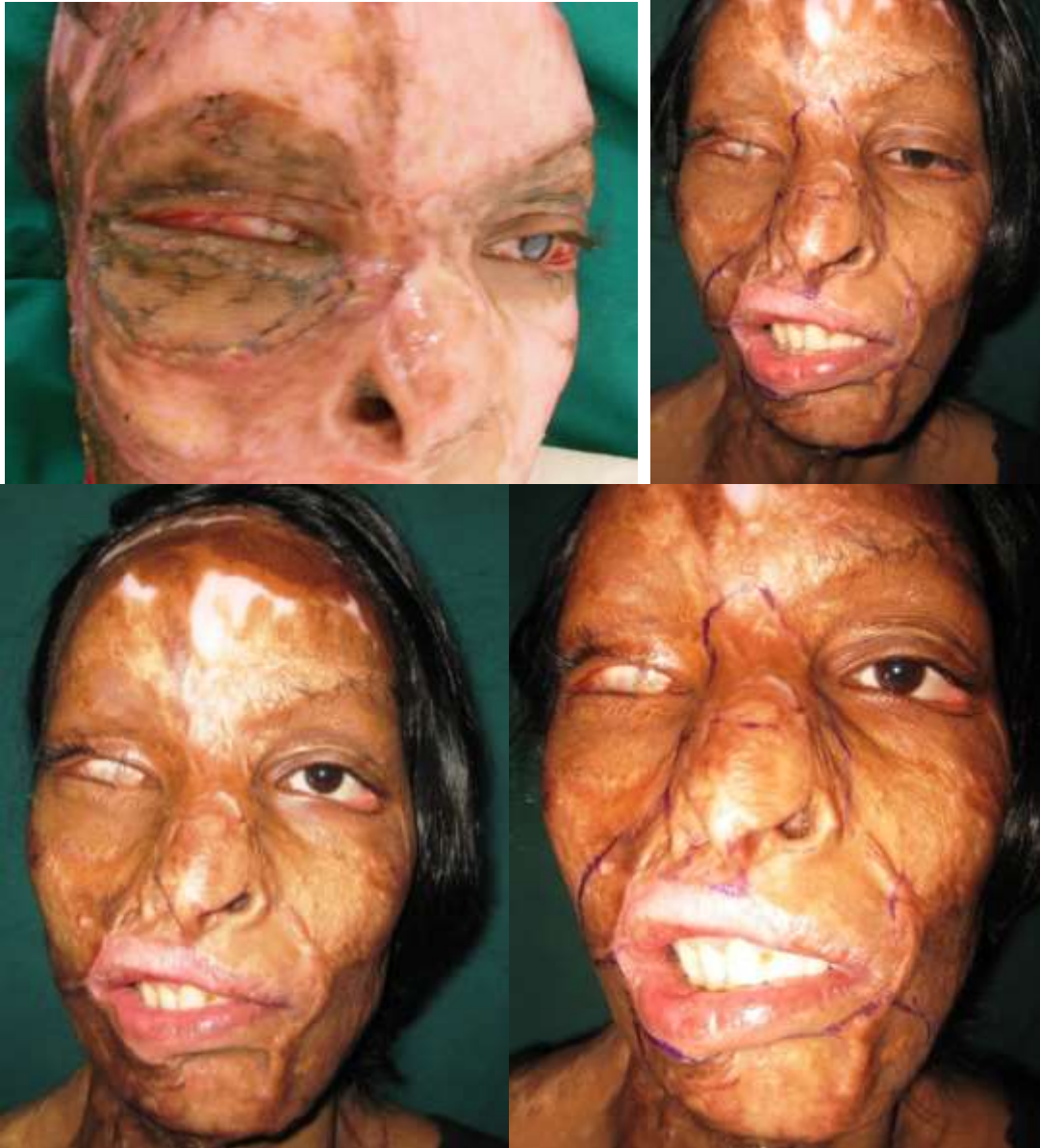Ms. L B B, aged about 21 yrs, a resident of **Azamgarh, U P**. She comes from a very small place. The only earning person is her father who works at a petrol pump in Mumbai with monthly income of Rs. 3000/-. The culprit was one of her relatives. Her appearance is traumatizing to the other patients. One of the patients on the adjoining bed told her visitor not to look in her direction and sent them out of the ward.



Due to severe neck contracture, induction of anaesthesia and intubation was not possible, hence to release the neck contracture under local anaesthesia had to be undertaken before start general anaesthesia. She has been operated upon on a number of occasions under general anaesthesia, wherein following procedures were done:



STORYLINE OF VICTIMS OF ACID ATTACK

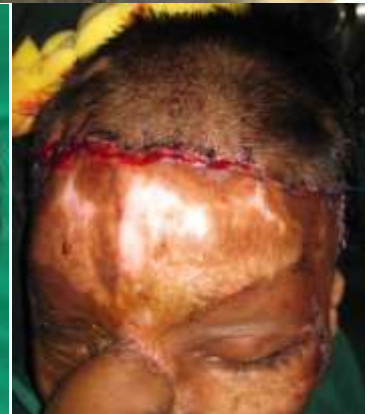
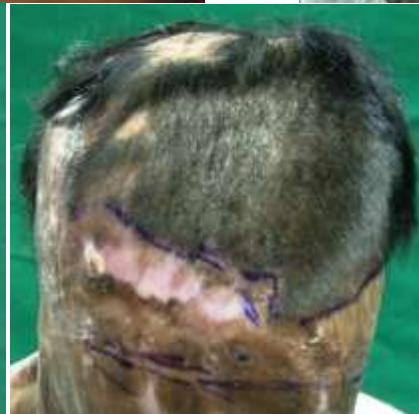
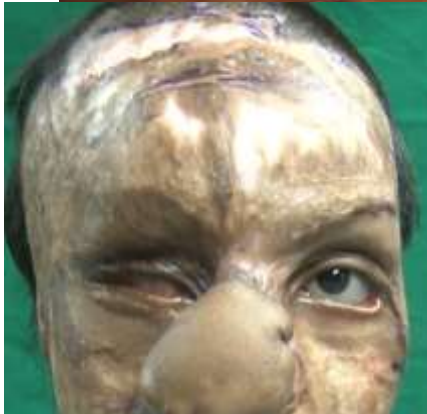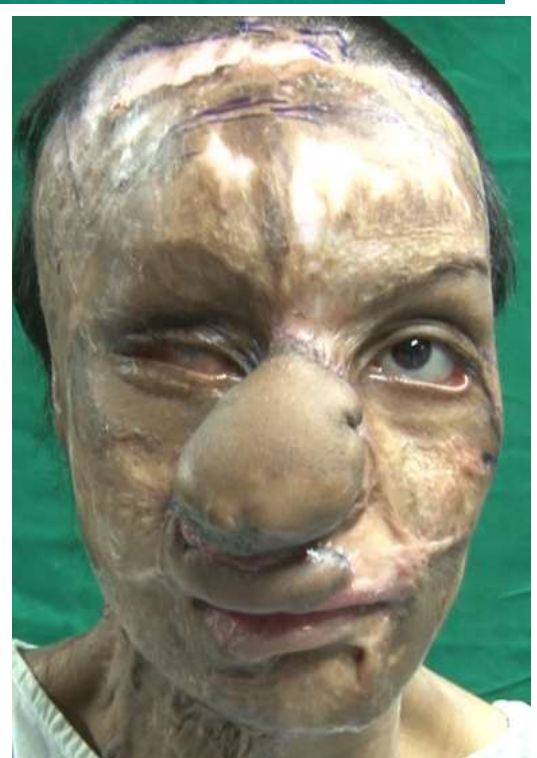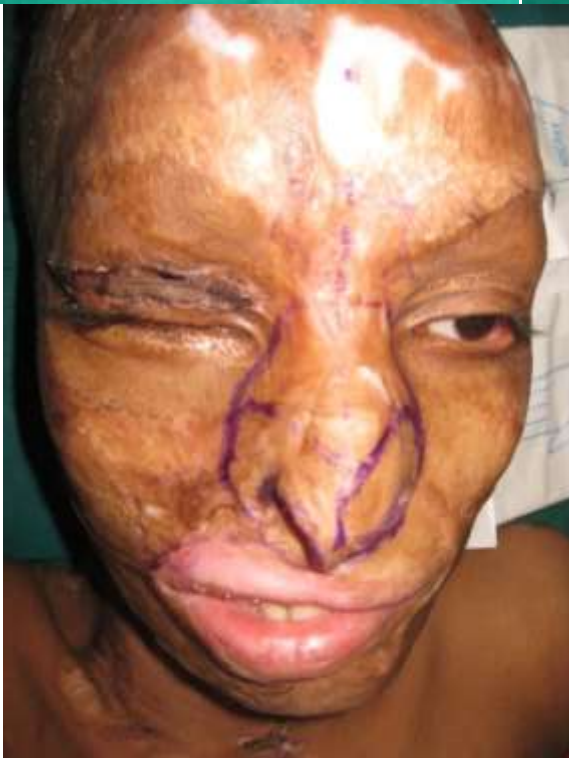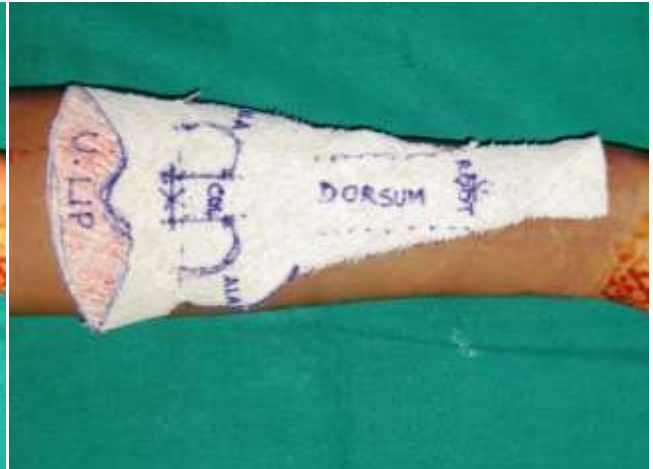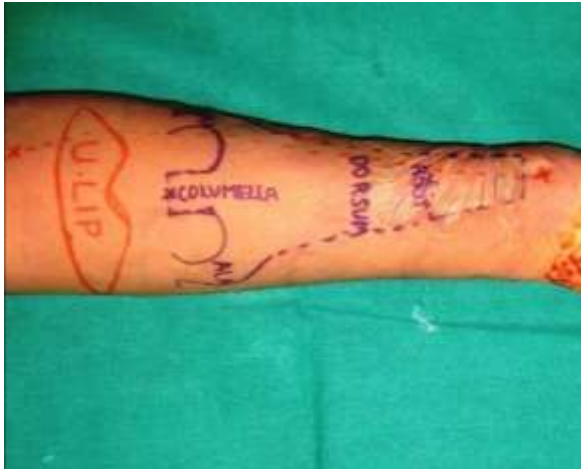Composite full / partial facial reconstruction using Pre-fabrication Technique to develop partial Nose + Upper lip + Cheek utilizing soft and pliable skin from the radial forearm flap + Extra Corporeal Transfer.

It is highly specialized multistage reconstructive procedure and need about 8 hours of surgical time for each of the stages.

- **Hair bearing skin flap from the vertico - occipital area of the scalp was used as rotation advancement flap to the frontal area**
- **The resultant raw area in the occipital area was covered with SSG.**
- **Multiple small Z plasty to correct the Ectropion lower Eyelid (L)**

STORYLINE OF VICTIMS OF ACID ATTACK



STORYLINE OF VICTIMS OF ACID ATTACK



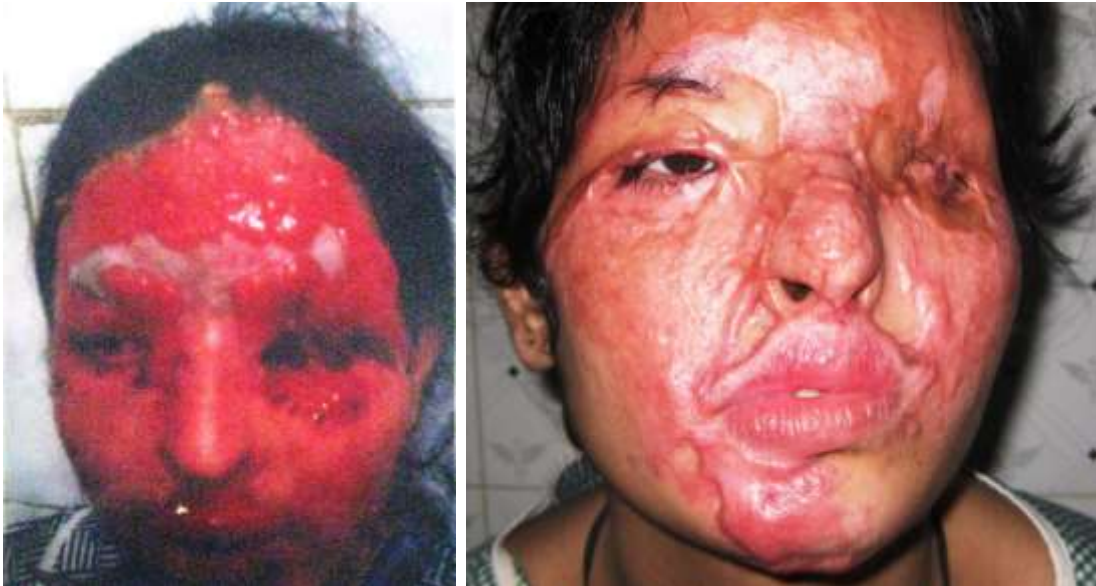She has recovered fully, married and even expecting a baby soon. She had participated in the Coveted “SAKSHAMA WALK” on the Floor with some of the well-known International professional Models / Bollywood Celebrities.

STORYLINE OF VICTIMS OF ACID ATTACK

2. Ms. R Q

Ms. R Q, aged about 20 years, a resident of **Mumbai**, a victim of acid burns, wherein her brother in law had thrown Acid on her face. She has been operated upon earlier on a number of occasions, wherein skin grafting had been undertaken. Her problems on admission with me were:

1. Tight, Hypertrophied, Hyper / Hypo-pigmented scars with significant skin and soft tissue loss on the Nose, Upper Lip, Chin and Forehead
2. Loss of Vision?? PL on one side
3. Post Burn total loss of Upper + Lower Eyelid structures (L)
4. Loss of Eye Lashes
5. Obliteration of Palpable Fissure on (L) side
6. Obliteration of Fornices on (L) side

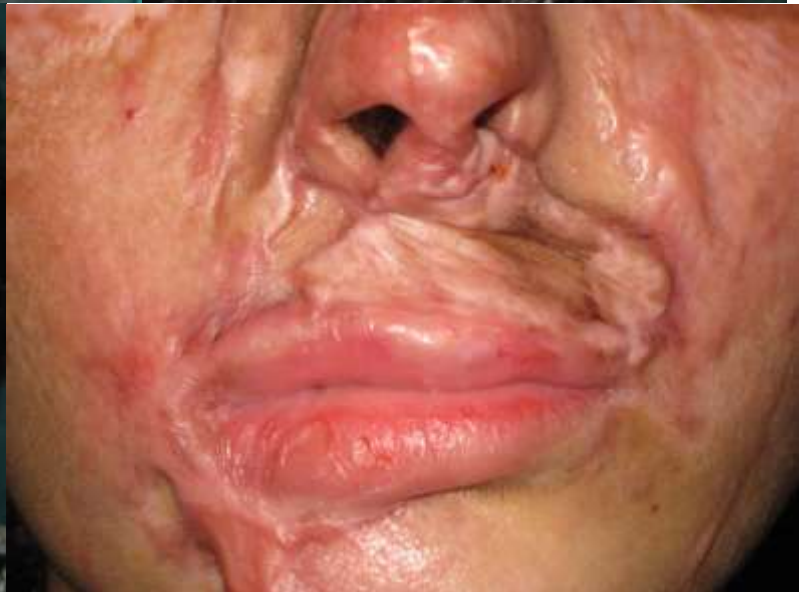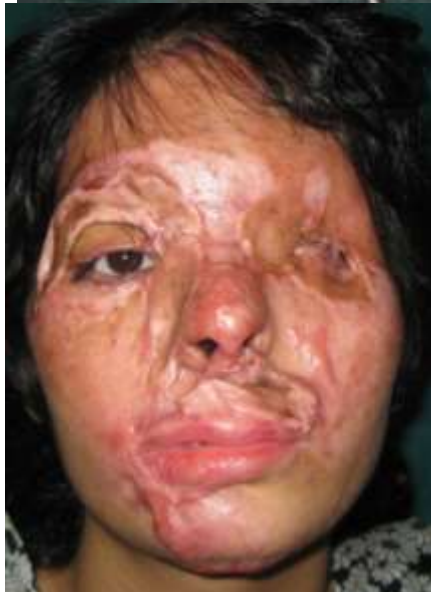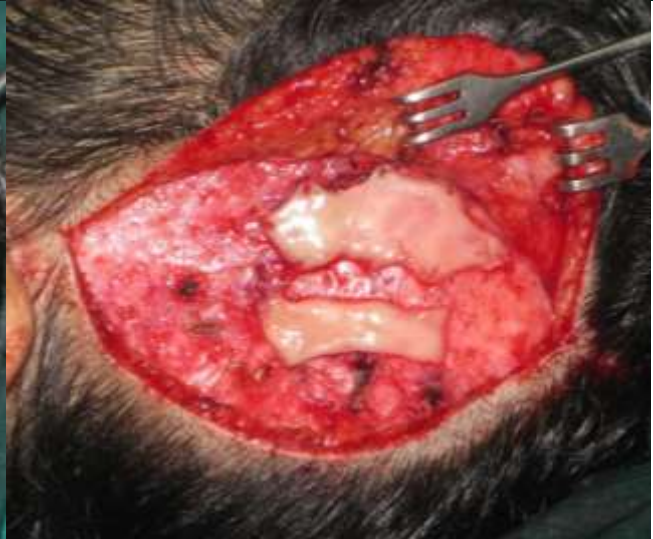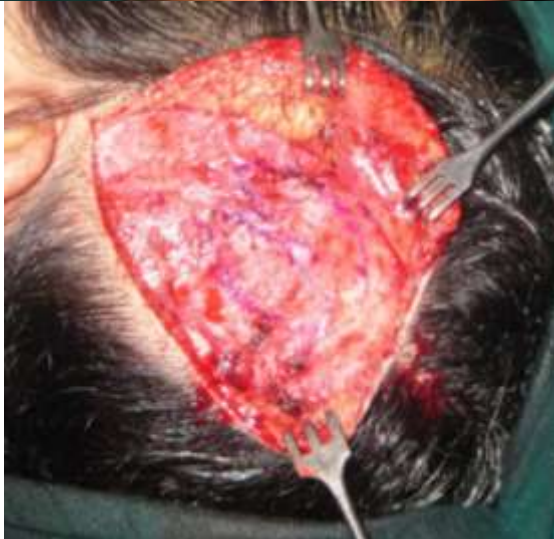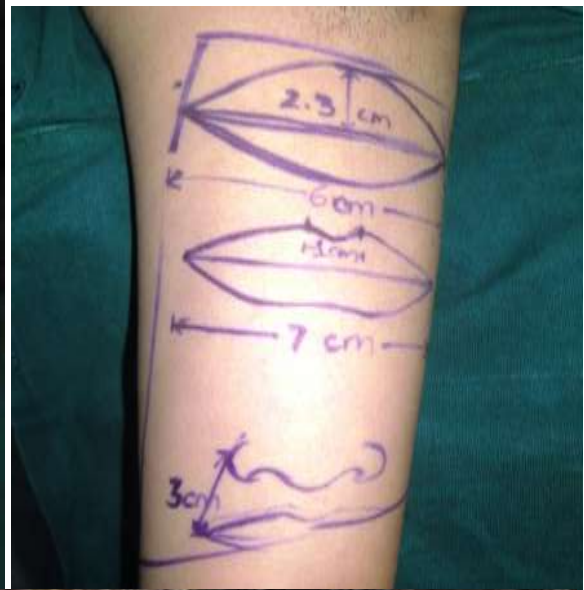


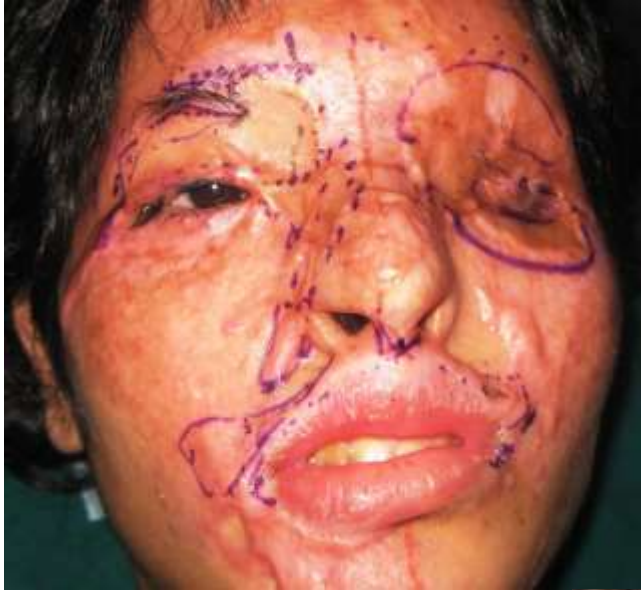She has been operated upon on a number of occasions over last two years utilizing specialized services of reconstructive microsurgery on a charitable basis under general anaesthesia and has made a significant recovery.

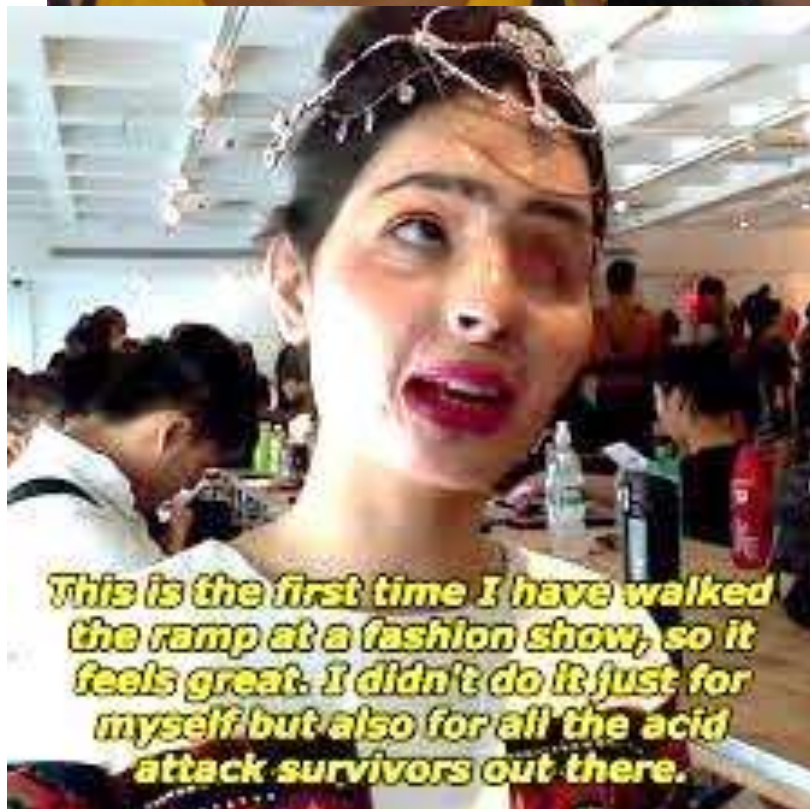
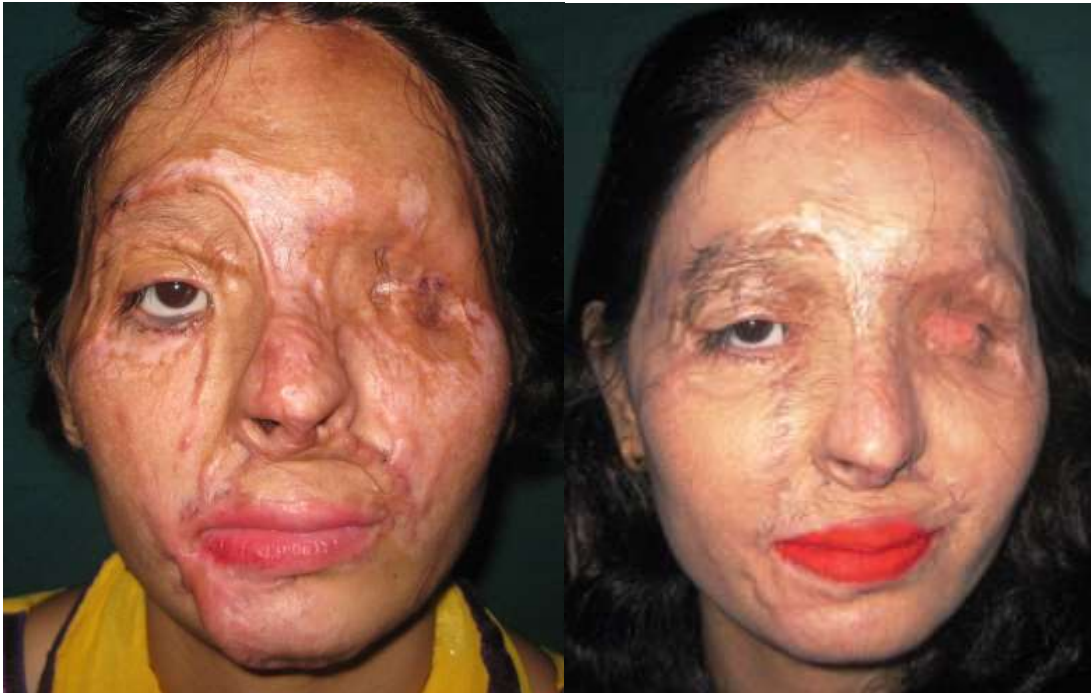Partial facial reconstruction using Pre-fabrication Technique to develop Upper + Lower lid utilizing lining with Mucosal Graft and thereafter soft and pliable skin from the medial side of the arm / forehead.

- Release of the Microstoma + Upper + lower lip + Multiple Z Plasties
- Excision of hypertrophic scar lower lip + chin + Multiple Z Plasties
- Autologous fat grafting under the scarred areas of the face.

STORYLINE OF VICTIMS OF ACID ATTACK



STORYLINE OF VICTIMS OF ACID ATTACK

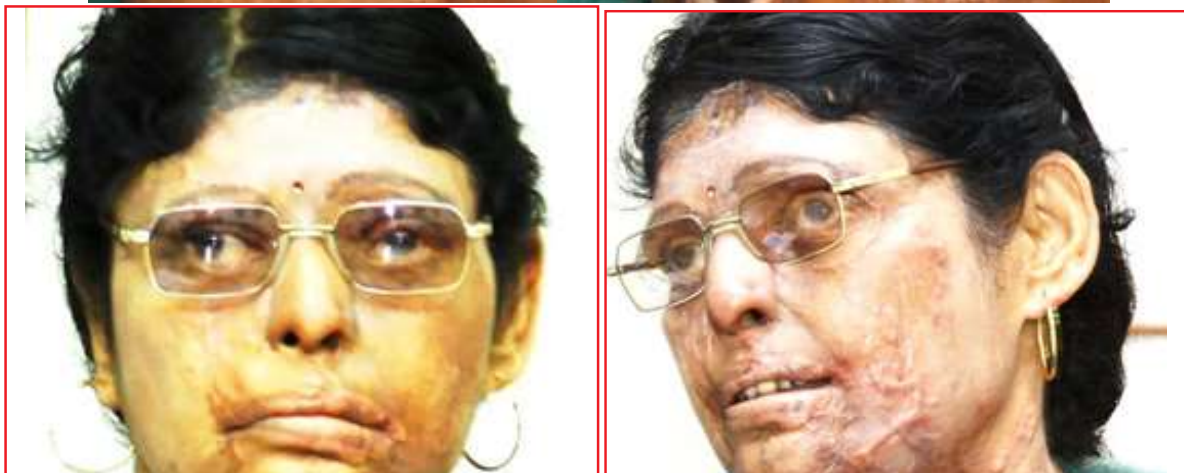
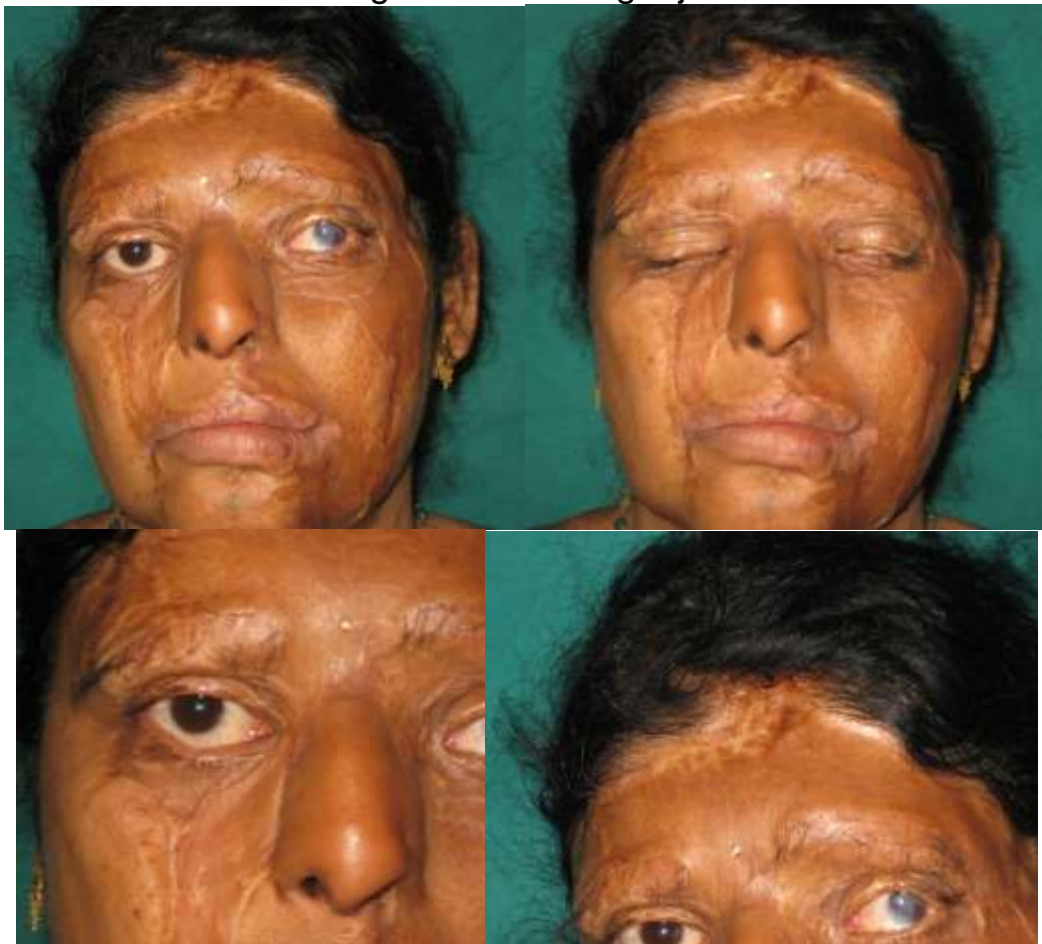
Currently, she has recovered fully and had actually participated in the Coveted “New York fashion Week” and walked on the Floor with some of the well-known International professional Models / Celebrities.

STORYLINE OF VICTIMS OF ACID ATTACK

3. Ms. K G

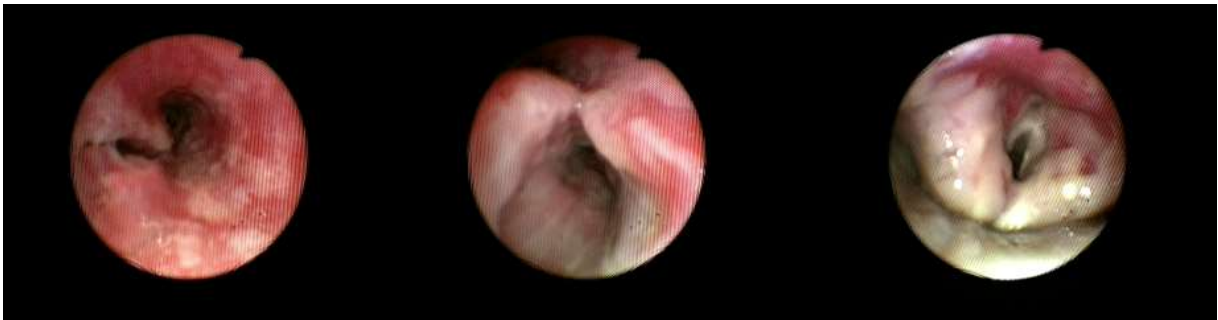Ms. K G, aged about 40 years, a resident of **Sangli**, was treated of various post burn deformities following Acid Throwing Injuries.



STORYLINE OF VICTIMS OF ACID ATTACK

4. Ms. P R

Ms. P R aged about 24 years, a resident of Narela, New Delhi, a **patient of** acid attack at Bandra Railway Terminus, Mumbai treated for various life threatening, function impairing and loss of vision deformities following Acid Throwing Injuries. She was kept on ventilator and her chest condition was not very good and was very critical. It was noted that she has gross edematous changes in the trachea and esophagus. Also, there is a communication between oesophagus and left main bronchus. Chest shows signs of chemical pneumonitis in right upper and middle lobe and left lower lobe. Right lower lobe partial collapse consolidation. Bronchoscopy was undertaken to evaluate trachea-bronchial tree and to determine extent of chemical damage and to do broncho-alveolar lavage and collection of secretions for culture and sensitivity.

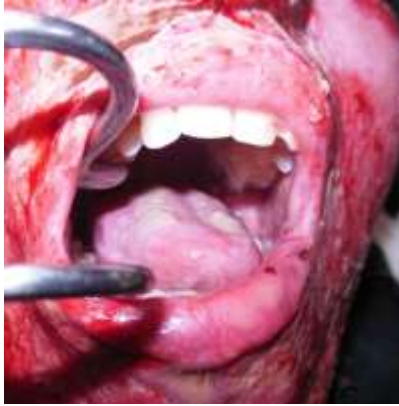

Broncho-esophageal fistula seen in posterior wall of left main bronchus approximately 1.00 cm long at 7- 8 O' clock position. The esophagus as is seen through the Fistula on bronchoscopy. Oro-pharyngeal region, Supra glottic region mucosa and the vocal cords are ulcerated and slough seen.

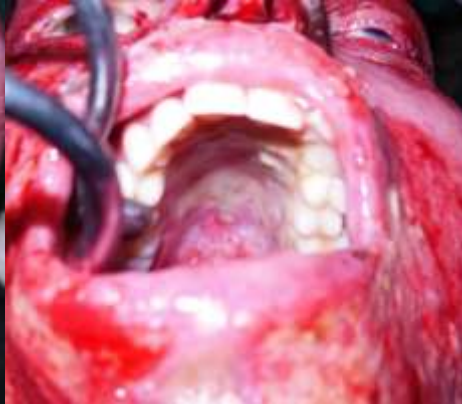She had developed life threatening complications of the direct injury to her lungs / trachea / esophagus and was further compounded by presence of a large Trachio-esophageal fistula. Due to critical nature of her condition, it was decided to install ECMO (**Extracorporeal Membrane Oxygenation**), which was made available and was later on made operational on her.

Intra oral damage was also assessed using the Bronchoscope, and it was noted that the floor of the mouth, the Tongue, the Hard Palate and the Vocal Cords are also severely damaged.

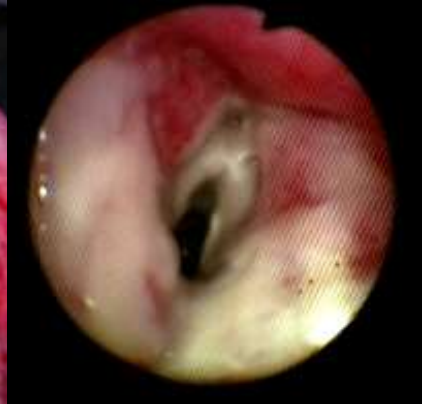STORYLINE OF VICTIMS OF ACID ATTACK



Intra Oral Tongue Burns

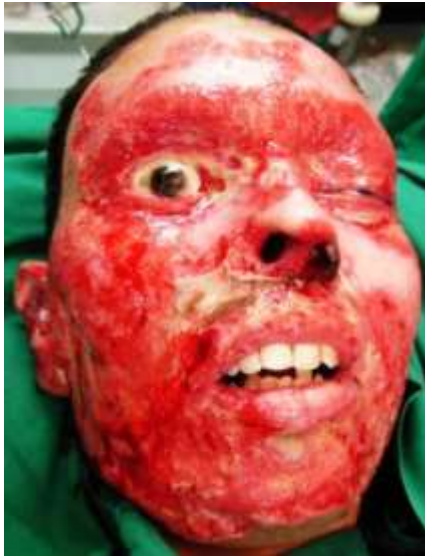

Intra Oral Palate Burns

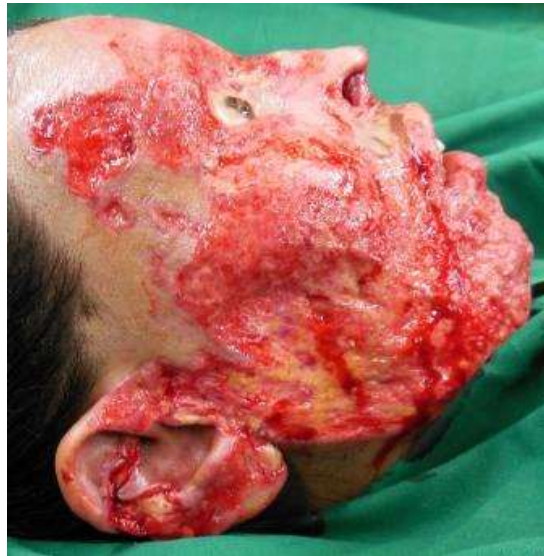

Intra Oral Vocal Cords

Simultaneously, wound debridement was carried out:



P R Face Front



P R Right Side Face

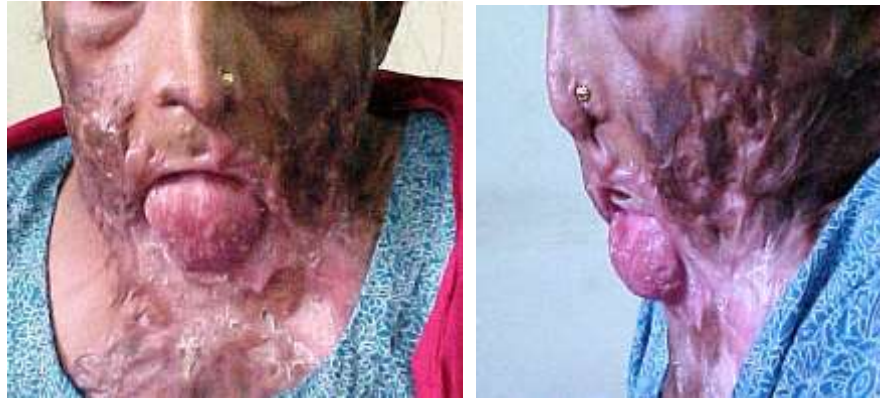Due to serious condition and associated septicaemia, poor lung function and multi organ, failure, she succumbed to the Burn Injuries.

She is the only case in the entire Country, wherein Capital Punishment was awarded to the Offender. Government of Maharashtra, established a Fast Track Court to tackle such cases on priority and based on the evidences provided by the Surgical team and looking at the Photographs, the Hon'ble Judge had no hesitations in awarding such a harsh punishment.

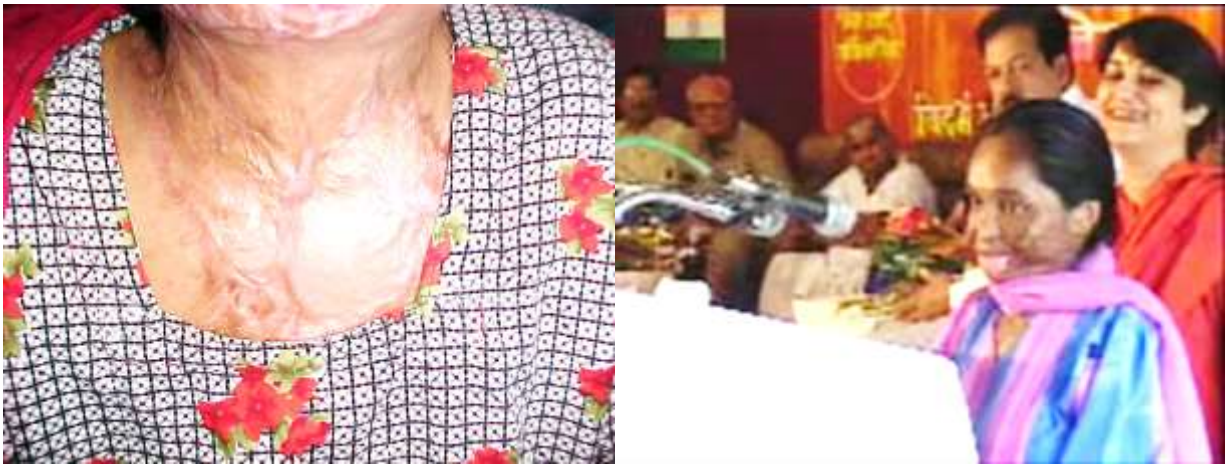STORYLINE OF VICTIMS OF ACID ATTACK

5. Ms. P A:

Post acid burn contracture was so severe that her lower lip practically touched the part of sternum. There was no extension and rotation at neck.



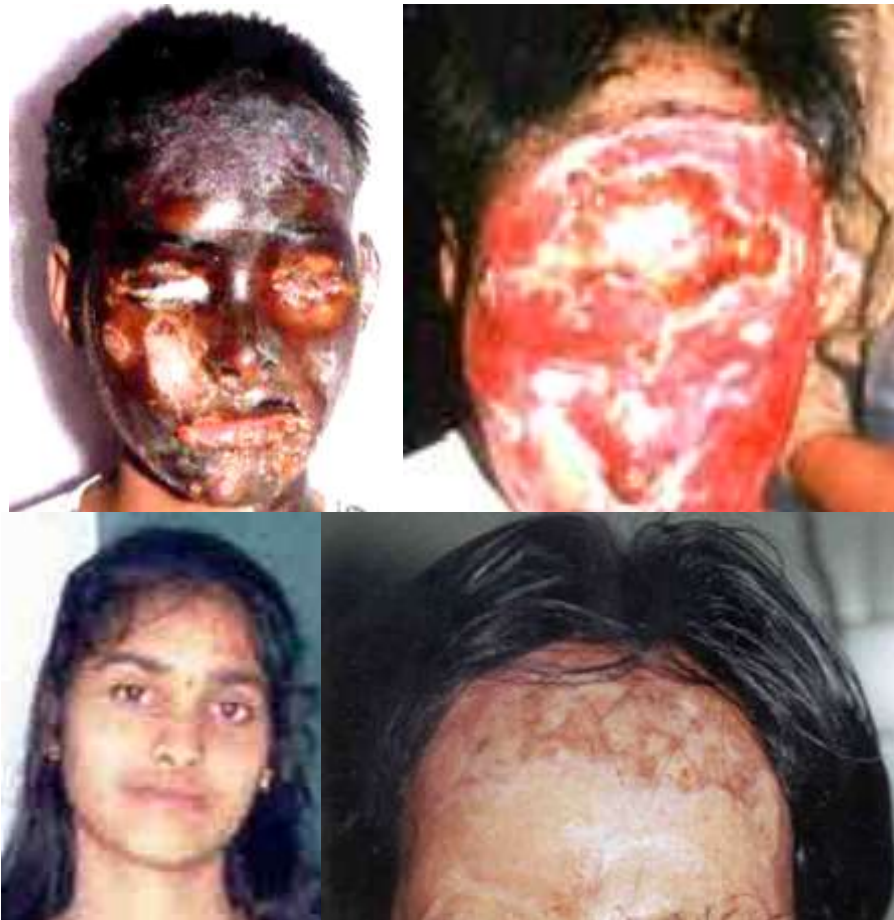She was examined during a free surgical session through the Reconstructive Surgery Foundation, and was advised to come to Mumbai for her treatment as it was too complex to be operated upon at the remote hospital, however she refused to come to Mumbai due to lack of resources. As well also threatened to commit suicide, if her surgery was not performed; Due to the severity of the neck contracture, full anaesthesia with endotracheal intubation was not possible hence; a senior anaesthesiologist was invited along with fibre optic laryngoscope. Her surgery was successfully performed and all the wounds and graft have healed well. Now PA has not only gone back to her normal life but has also become an active volunteer for all surgical.



STORYLINE OF VICTIMS OF ACID ATTACK

6. ACID ATTACK IN CUTTACK P S:

16-year-old PS was a bubbly teenager. Today, she is alive but life for her seems worse than death. While on her way to college, PS and three of her friends were waylaid by six men. While her friends watched in horror, unable to help, the men caught hold of PS and poured acid all over her face. The main culprit, was caught by passers-by but his accomplices escaped. Though PS was rushed to hospital, it was too late. It had taken just a few seconds for the acid to mangle her face and chest. PS 's brother had hired culprit, an electrician, to repair their TV set. Having taken a fancy to the Class X student he saw in the house, culprit began stalking her, often stopping her on the street and proposing to her. She told her father about culprit's behaviour. Angered by her rejection, the obsessed man finally took revenge by attacking the girl with acid and ruining her life.

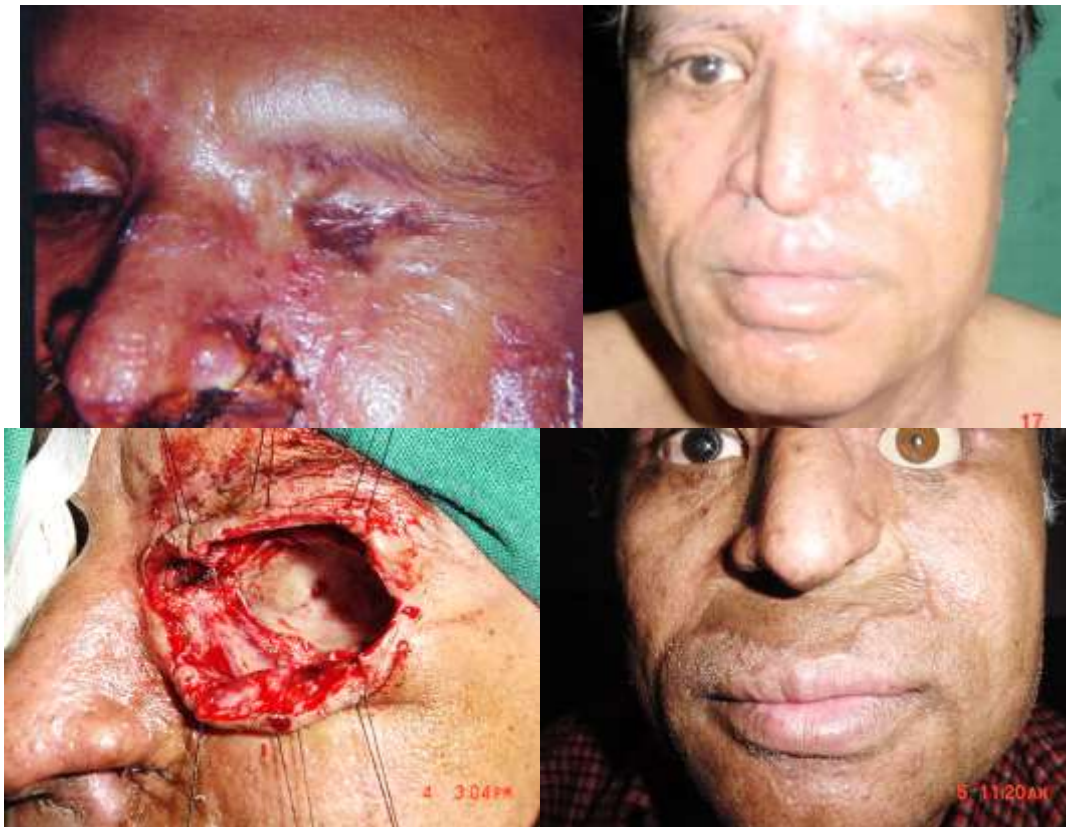

PS has a long way to go before she can hope to look anything like her old self. The priority is to restore her eyelids which have been virtually destroyed; her ears, nose and mouth also need reconstruction operations.

STORYLINE OF VICTIMS OF ACID ATTACK

7. ACIDIC LABOR-UNION DISPUTE G P:

GP was an accountant and manager at a bank. Everything in his life was going smooth, until his promotion from the post of accountant to manager. GP got caught in the cob web of labor-union dispute, where he supported the labourers, and as a result of anger the union leader of the bank threw acid on his face. GP suffered from great trauma mentally and physically.



GP suffered from acid burn deformities involving eyelid, mouth, neck and chest. He was then operated for different stages almost 24 times. Initial treatment was removal of dead skin and application of thin skin graft followed by definitive corrective surgery, by using full thickness skin graft.

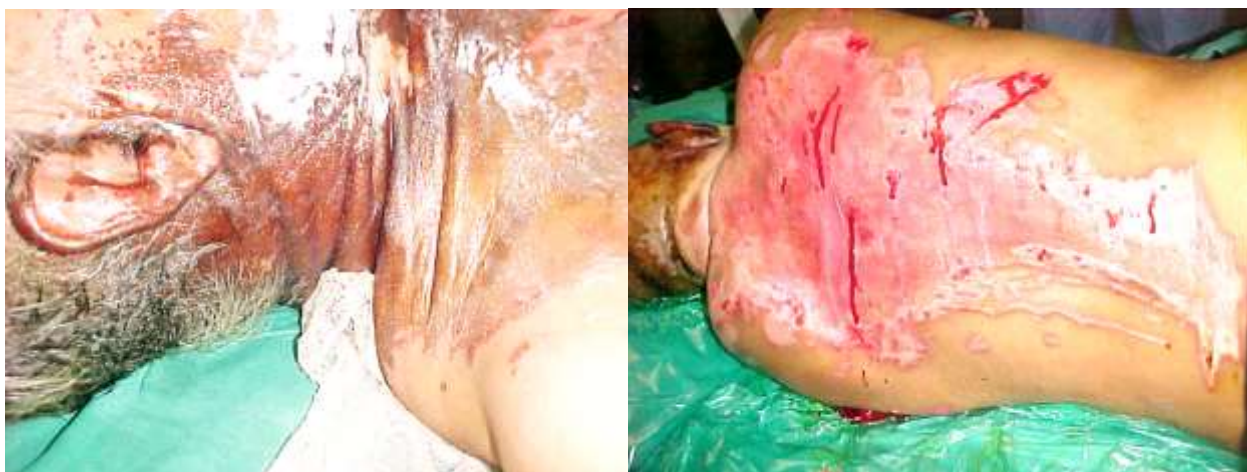Despite the numbers of surgeries, GP could not go back to his previous job as he still faced disgusted stares, abuses, and mockery. Hence he was given retirement by his employer to relieve him of the everyday suffering. It was a great loss of earning and self-respect for the entire family to suffer with no faults of theirs.

STORYLINE OF VICTIMS OF ACID ATTACK

8. ACIDIC LABOR-UNION DISPUTE A G

A G, Male aged around 64 years, was a Senior Engineer and Site Manager at a big Industrial Unit of a Limited Company. Everything in his life was going smooth, until his commitment and time schedule made him hard pressed to work extra to finish the project for launch within stipulated time.

A G got caught in the labor-union dispute, and the union leader threw the entire can filled with acid on his face and body. A G suffered 45% deep burns with shock. He was immediately rushed to the ICU and later air lifted to the specialized unit for the treatment.



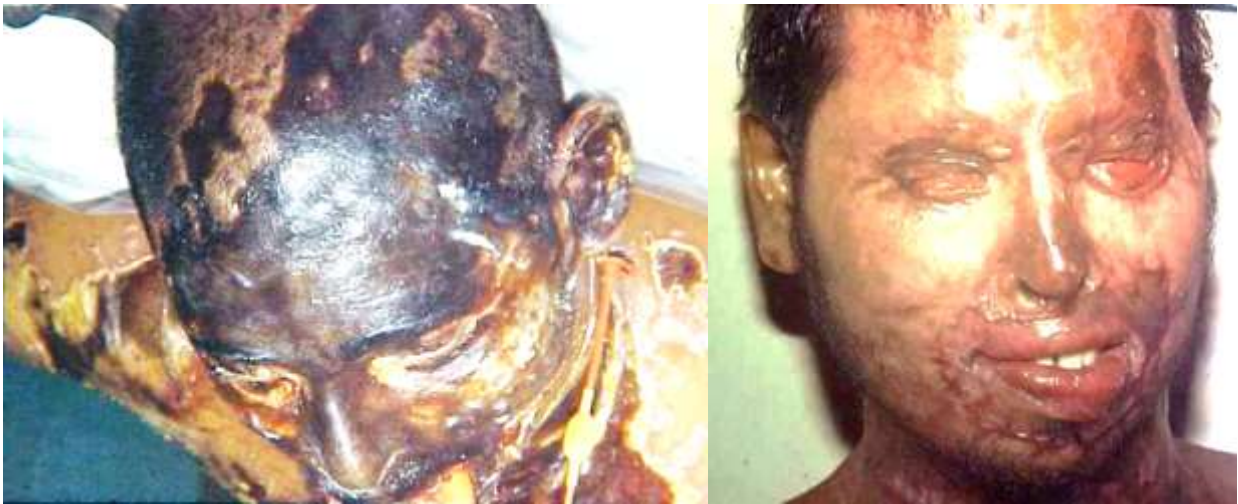A G suffered from acid burn deformities involving face, neck, arms and back. He was operated for different stages almost 12 times as life-saving procedure. Initial treatment was to stabilize him, prevent toxins spreading in to his circulation and prevent infection. Thereafter, he underwent removal of dead skin and application of thin skin graft over several surgical sessions.

Although, A G could go back to his previous job, however the scares and abuses haunted him. Hence he opted for VRS retirement to overcome the everyday suffering and went into social and professional isolation.

STORYLINE OF VICTIMS OF ACID ATTACK

9. SEAMAN'S FUTURE BEING RUINED : A BURNED FACE

S M was a young and energetic Seaman. However due to his this professional efficiency, he developed some jealous friends. One evening, while holidaying with his group, following a fight on very trivial issue, landed up in fight with a friend due to same professional efficiency. The friend took the opportunity and heartlessly splashed acid on the face on the young and energetic Seaman. Eyes, face, and neck of SM got severely burned. He lost vision on both the eyes. He had to stop the carrier and is in darkness since then. He suffered not only physical loss but also financial loss. His dream of making it big in maritime industry was shattered before even it started.



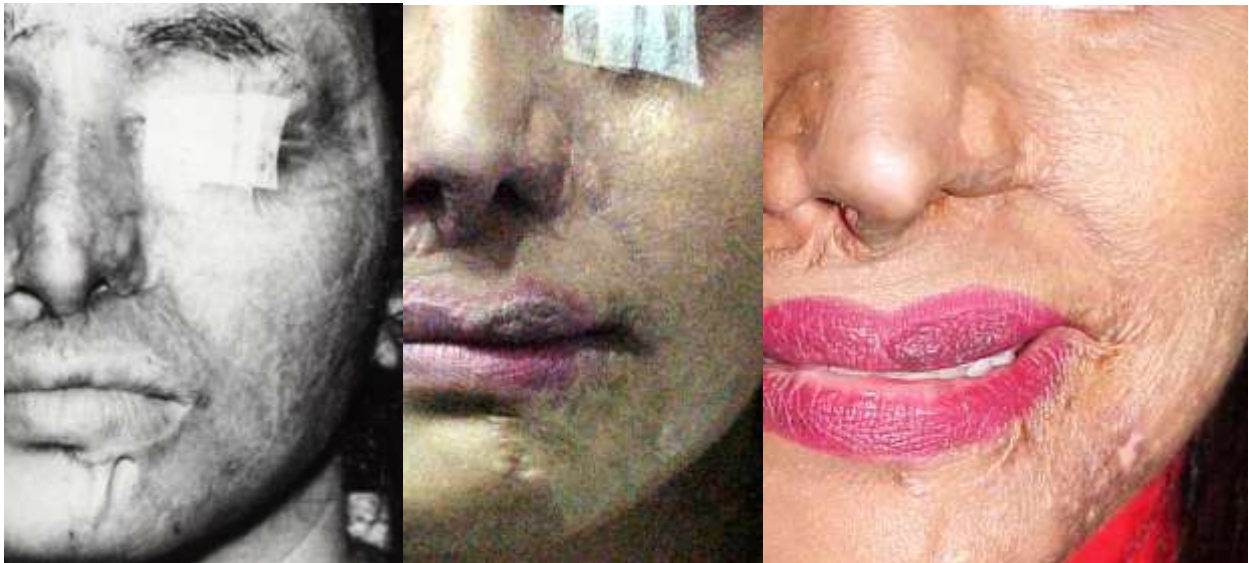S M has undergone series of reconstructive surgeries and procedures including skin graft, flap and tissue expander. However, his results still remains far from satisfactory. He still has no vision on both the eyes and is entirely dependent on his family support for even basic needs. It was a great loss of earning and self-respect for the entire family to suffer with no faults of theirs.

He would be an ideal patient for a Total face Transplant, if possible in future.

STORYLINE OF VICTIMS OF ACID ATTACK

10. CAUSELESS ATTACK, INJURING A TEENAGER

Resident at Bandra, 42 yrs, came with history of accidental burn. She was apparently all right till 14 years of age and studying in 9th standard. While waiting for the School Bus, someone threw acid on her face. She was immediately hospitalized in a state of shock and it was only after 3 months, she realized what had happened to her and asked her parents about the incident. She had complete amnesia to the incident. She just thought that maybe she was a bad person and deserved this punishment, thus this incident has happened to her.



Since then life was a struggle. She was operated upon repeatedly. She became very bold and would go to markets and shopping with the bandage. She lost her left eye, during this period. After losing eye sight she developed depression and spent most of the time at home. Then there was a dramatic change in her. She became very bold. She would not hesitate talking to anyone; there was no hesitation even with strangers. She is bold and extrovert. She started enjoying her life to the fullest; she also made friends with opposite sex and enjoying male company. She loves wearing attractive and modern clothes and accessories.

She wanted to show the world that nothing in the world can stop her from reaching her goal and feels comfortable at all places. She overcame all the odds and became a leading Fashion Designers and held several shows across the nation and the world.

She has become a role model for several of such acid attack victims.